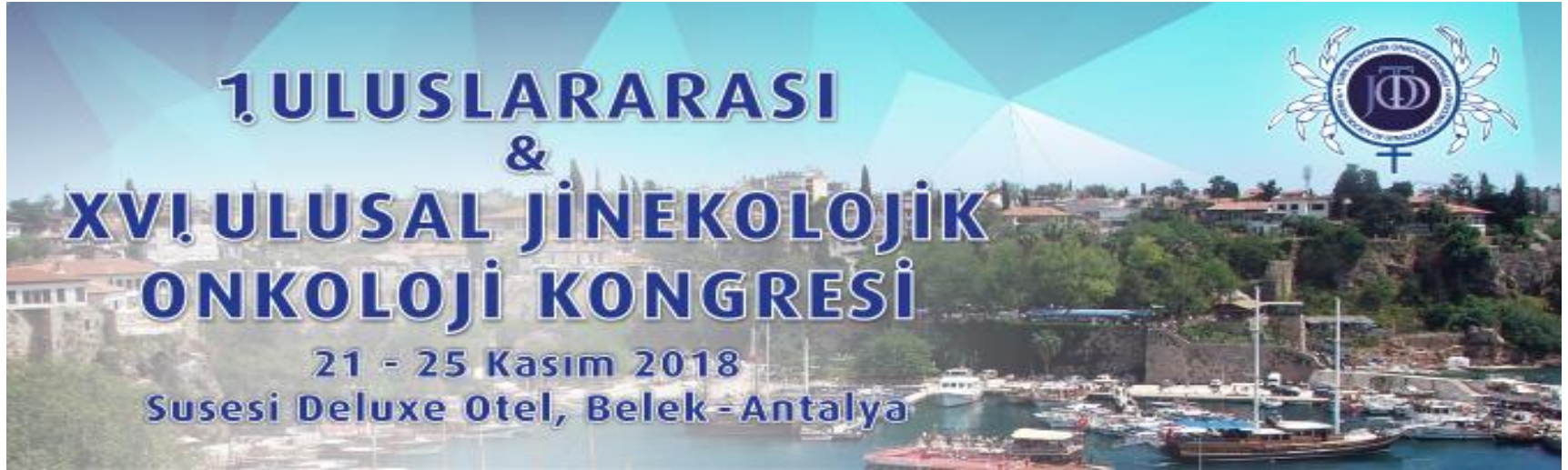

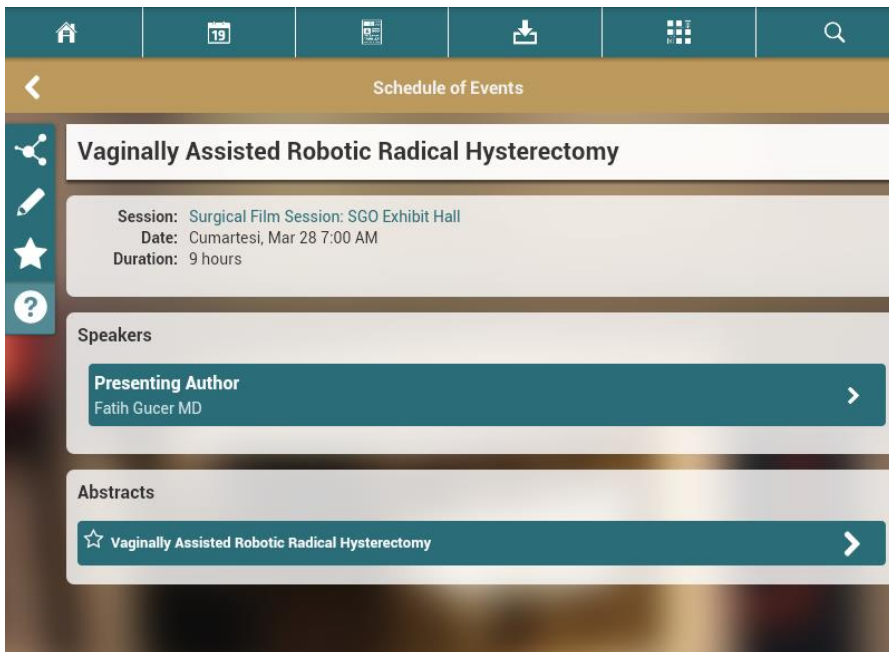


Vaginally Assisted Robotic Radical Hysterectomy

Fatih Güçer, MD
Anadolu Medical Center
Istanbul, Turkey



2015
ANNUAL MEETING
ON WOMEN'S CANCER[®]
March 28-31 CHICAGO



Home | 19 | | Download | | Search

< Schedule of Events

Vaginally Assisted Robotic Radical Hysterectomy

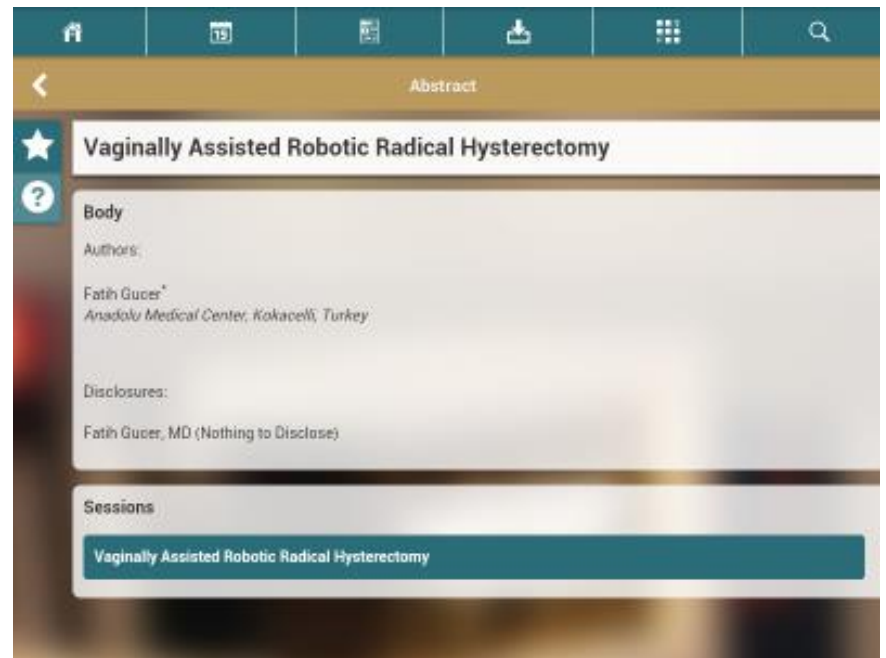
Session: Surgical Film Session: SGO Exhibit Hall
Date: Cumartesi, Mar 28 7:00 AM
Duration: 9 hours

Speakers

Presenting Author
Fatih Gucer MD

Abstracts

☆ Vaginally Assisted Robotic Radical Hysterectomy



Home | 19 | | Download | | Search

< Abstract

☆ **Vaginally Assisted Robotic Radical Hysterectomy**

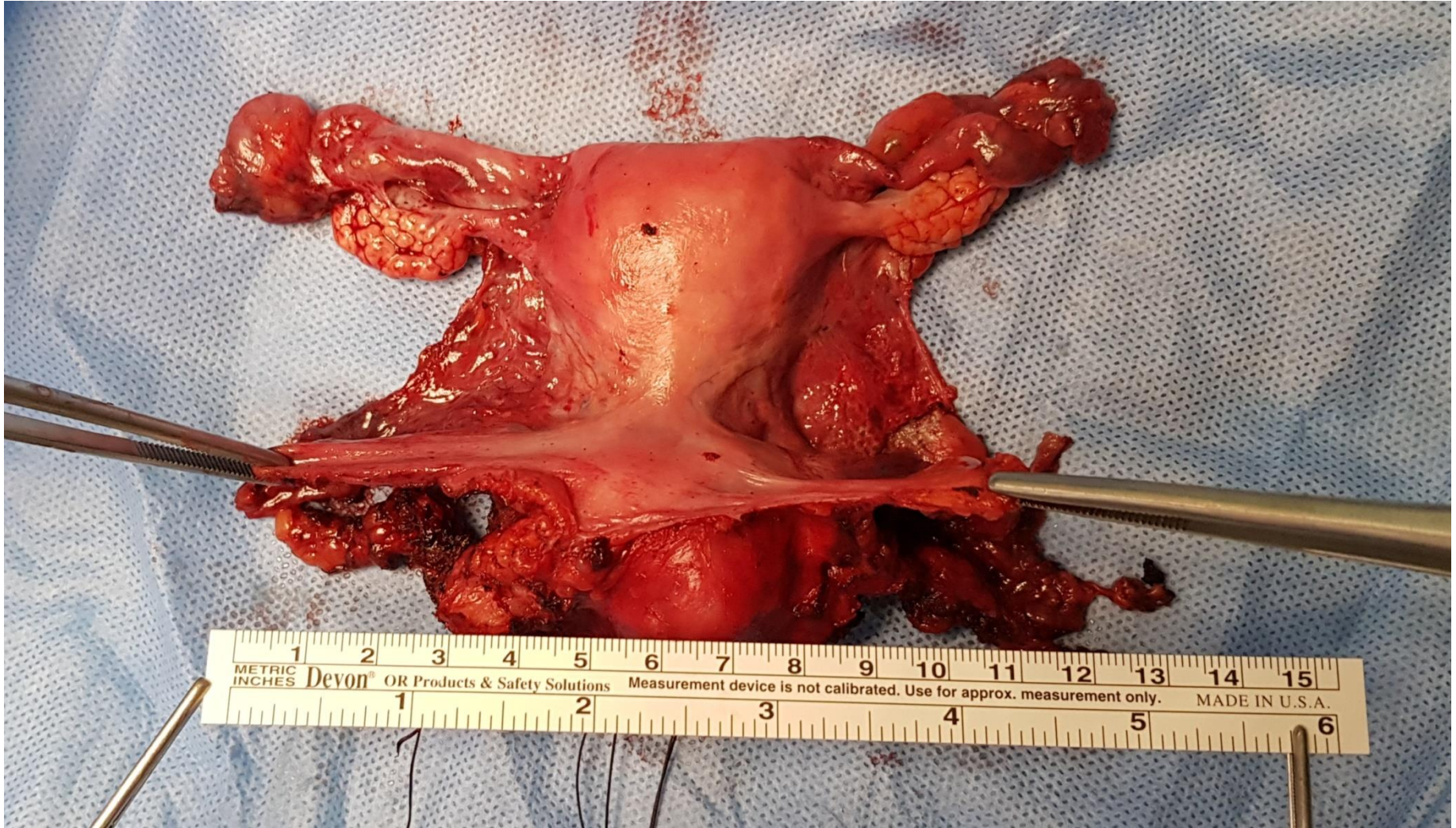
Body

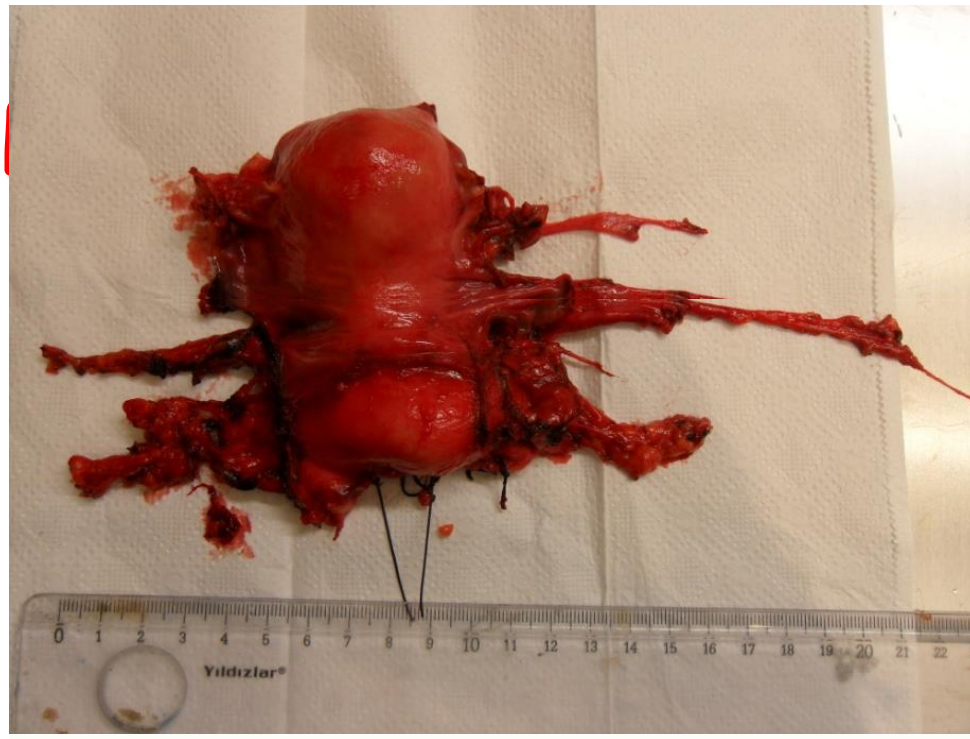
Authors:
Fatih Gucer*
Anadolu Medical Center, Kokaceli, Turkey

Disclosures:
Fatih Gucer, MD (Nothing to Disclose)

Sessions

Vaginally Assisted Robotic Radical Hysterectomy





PARAMETRIAL SPREAD WITH NEGATIVE PELVIC LYMPH NODES

253

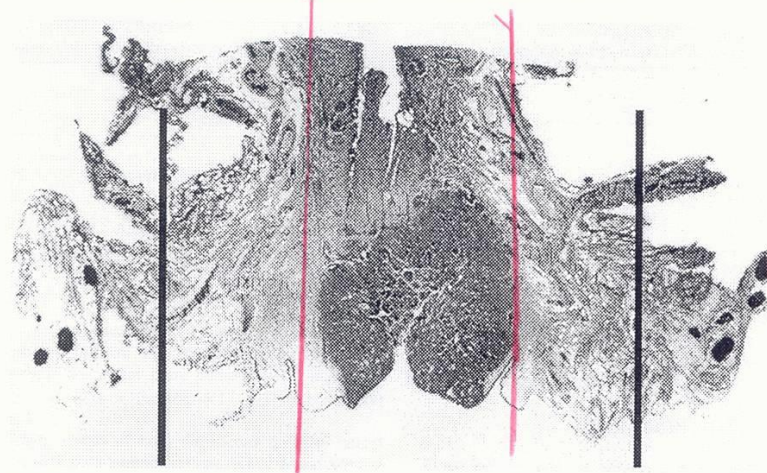


FIG. 1. Frontal giant section through the cervix and both parametria. The uterine corpus has been amputated. The solid lines show the extent of parametrial resection with modified radical hysterectomy and radical (type III) hysterectomy.